

Eccrine Syringofibroadenoma: A Rare Skin Adnexal Tumor at a Rare Site

Dear Editor,

Eccrine syringofibroadenomas (ESFAs) are rare benign skin adnexal tumors (SATs) that arise from cells of the acrosyringium of eccrine sweat glands.^[1] Clinically, varied phenotypes have been reported but histological findings of ESFA are classical, enabling the dermatologist to arrive at a conclusive diagnosis.

The three characteristic findings identified on histopathology in ESFA include:

- Narrow strands of basaloid acrosyringial cells arranged as anastomosing cords extending into the dermis.
- Duct formation.
- Mucinous fibrovascular stroma.

Our patient was a 25-year-old male, who presented with an asymptomatic, pinkish white fibrotic nodule over the scalp of size 2×2.5 cm [Figure 1]. He noticed this since the past 7 months and the lesion had gradually progressed

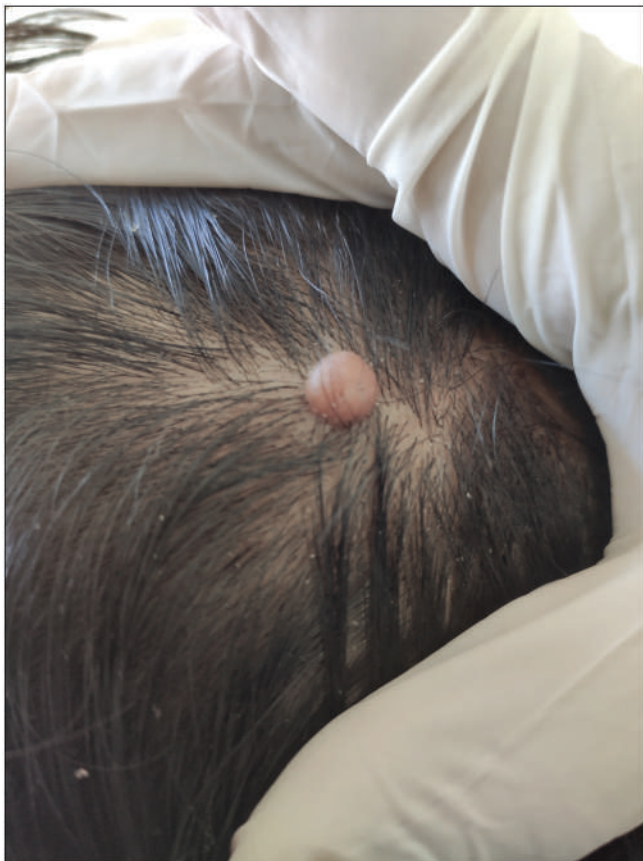

Figure 1: A solitary pinkish white fibrotic nodule on the scalp

to attain the current status. A provisional diagnosis of fibroma and SAT were considered and an excision biopsy was performed. Skin biopsy revealed thin anastomosing cords of epithelial cells arising from the epidermis and extending toward the dermis [Figures 2 and 3].

A ductule lined by cuboidal cells was also identified in association with the epithelial strands suggesting eccrine differentiation [Figure 4]. With the aforementioned findings, a diagnosis ESFA was confirmed.

Five clinical subtypes of ESFA exist; namely:

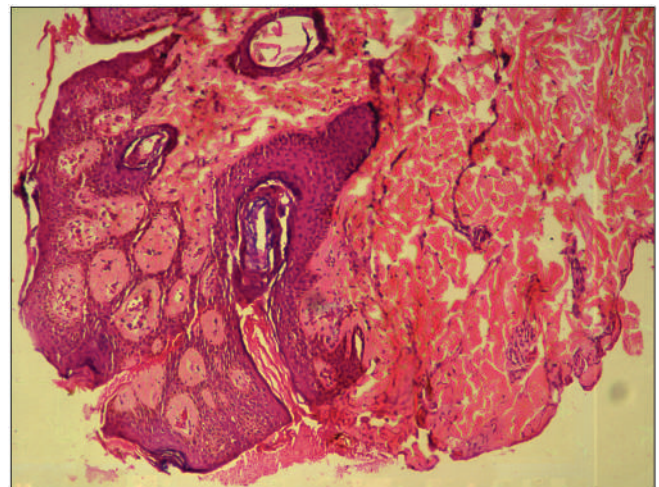


Figure 2: Thin anastomosing cords of epithelial cells arising from the epidermis and extending to the dermis (H&E ×40)

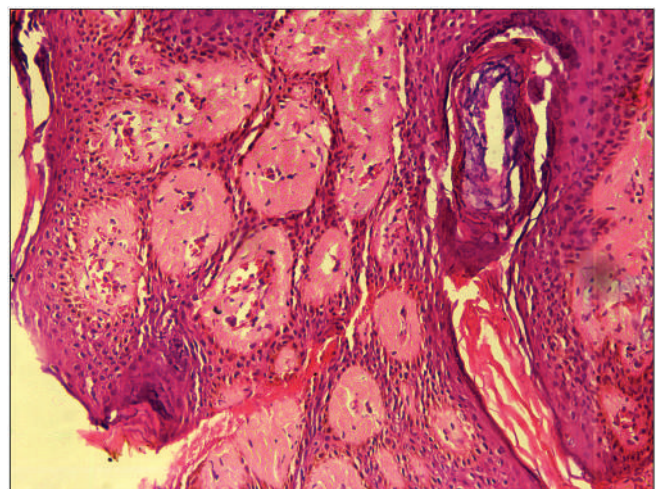


Figure 3: Higher magnification of anastomosing cords composed of epithelial cells (H&E ×100)

Table 1: Various reports of solitary eccrine syringofibroadenomas in the past, including our case

Serial number	Author(s)	Year	Age/sex	Duration	Symptoms	Location	Morphology
1.	Bottino et al. ^[2]	2015	81 years/female	3 years	Painful	Right lateral malleoli	Erythematous tumor-like plaque with small central ulceration
2.	Arora et al. ^[3]	2015	62 years/male	1 year	Painful	Distal phalanx of left index finger	Sharply demarcated nodular plaque with thick, adherent scales and a warty, keratotic surface
3.	Hurt et al. ^[4]	1990	48 years/male	1 year	Asymptomatic	Right lumbar region	A solitary 10 × 7 mm papule
4.	Kanitakis et al. ^[5]	1987	80 years/male	—	—	Right great toe	Solitary nodule resembling granuloma pyogenicum
5.	Mehregan et al. ^[6]	1985	72 years/male	15 years	—	Left wrist	5 × 2.5 cm solitary, verrucous, and nodular growth partially covered by a layer of crust
6.	Olmos ^[7]	1980	67 years/female	—	—	Right hypochondrium	Solitary nodule
7.	Civatte et al. ^[8]	1981	60 years/male	—	—	Right leg	Solitary nodule
8.	Iqbal et al. ^[9]	2019	42 years/male	—	Painful	Scalp	Erythematous tender swelling 2.5 × 2 cm resembling a dermoid cyst
9.	Our patient	2021	25 years/male	7 months	Asymptomatic	Scalp	Pinkish white fibrotic nodule

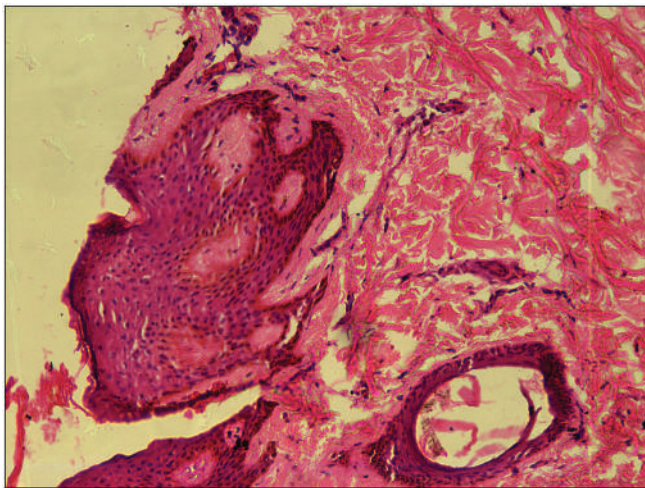


Figure 4: A ductule lined by cubical cells in association with epithelial strands, suggesting eccrine differentiation (H&E ×100)

- Solitary ESFA;
- Multiple ESFA associated with ectodermal dysplasia;
- Multiple ESFA without cutaneous features;
- Unilateral linear ESFA; and
- Reactive ESFA associated with inflammatory or neoplastic dermatosis.

Our patient belonged to the solitary ESFA subtype. Past medical literature elaborates very few reports on solitary non-reactive ESFAs; details of which have been outlined in Table 1.

After studying the above reports (pertaining to solitary ESFA), we observed that the extremities constituted the most common site of involvement. Scalp involvement, on the other hand was described in only one previous publication.^[9] We would hereby like to highlight our case firstly, owing to the rare fibrotic nodular morphology encountered and secondly its involvement of the scalp (an uncommon site for ESFA).

Histopathology findings reported in our patient were classical for this entity and that enabled clinching the diagnosis. Immunohistochemistry, though not mandatory with this classical histopathology may be required for diagnosis in some less typical presentations to confirm eccrine origin of the SAT.

To conclude, all dermatologists should be familiar with the histopathological pattern of ESFA, so that the diagnosis of ESFA is not missed. The standard treatment for solitary ESFA is surgical excision.

Declaration of patient consent

The authors certify that they have obtained all appropriate patient consent forms. In the form the patient(s) has/have given his/her/their consent for his/her/their images and other clinical information to be reported in the journal. The patients understand that their names and initials will not be published and due efforts will be made to conceal their identity, but anonymity cannot be guaranteed.

Financial support and sponsorship

Nil.

Conflicts of interest

There are no conflicts of interest.

Nitin K. Patil, Aditya K. Bubna, Seeba Hussain, Leena D. Joseph¹

Department of Dermatology, Katihar Medical College, Karim Bagh, Katihar
854106, Bihar,

¹Department of Pathology, Sri Ramachandra University, Porur, Chennai 600116,
Tamil Nadu, India

Address for correspondence: Dr. Aditya Kumar Bubna,
Department of Dermatology, Katihar Medical College, Karim Bagh, Katihar
854106 Bihar, India.
E-mail: zimbabwa21@gmail.com

REFERENCES

- Dongre AM, Nikam VV, Pathave HS, Malladi N. Perianal eccrine syringofibroadenoma. *Indian J Dermatol* 2017;62:548.
- Bottino CB, Guimarães TF, Gomes FR, D'Acri AM, Lima RB, Martins CJ. Solitary eccrine syringofibroadenoma—Case report. *An Bras Dermatol* 2015;90:235-8.
- Arora P, Bansal S, Garg VK, Khurana N, Lal B. Solitary eccrine syringofibroadenoma with nail involvement: A rare entity. *Indian J Dermatol* 2015;60:103.
- Hurt MA, Igra-Serfaty H, Stevens CS. Eccrine syringofibroadenoma (Mascaró). An acrosyringal hamartoma. *Arch Dermatol* 1990;126:945-9.
- Kanitakis J, Zambruno G, Euvrard S, Hermier C, Thivolet J. Eccrine syringofibroadenoma. Immunohistological study of a new case. *Am J Dermatopathol* 1987;9:37-40.
- Mehregan AH, Marufi M, Medenica M. Eccrine syringofibroadenoma (Mascaró). Report of two cases. *J Am Acad Dermatol* 1985;13:433-6.
- Olmos L. Syringofibroadenoma ecrino de Mascaró. *Actas Dermo Sitoligr* 1980;71:73-6.
- Civatte J, Jeanmougin M, Barrandon Y, Jiménez de Franch A. [Mascaró's eccrine syringofibroadenoma. Discussion of a case]. *Med Cutan Ibero Lat Am* 1981;9:193-6.
- Iqbal B, Khandekar P, Dey I, Kumar H. Syringofibroadenoma: Benign eccrine sweat gland tumor—A rare case report. *Indian J Dermatopathol Diagn Dermatol* 2019;6:97-9.

This is an open access journal, and articles are distributed under the terms of the Creative Commons Attribution-NonCommercial-ShareAlike 4.0 License, which allows others to remix, tweak, and build upon the work non-commercially, as long as appropriate credit is given and the new creations are licensed under the identical terms.

For reprints contact: reprints@medknow.com

Access this article online

Quick Response Code:



Website:

www.jcasonline.com

DOI:

10.4103/JCAS.JCAS_28_21

How to cite this article: Patil NK, Bubna AK, Hussain S, Joseph LD. Eccrine syringofibroadenoma: A rare skin adnexal tumor at a rare site. *J Cutan Aesthet Surg* 2022;15:335-7.